

Cold Abscess of Bilateral Parotids: Delusion or Reality?

Chaitra Udagi¹, Pooja Jaisinghani^{1*}, Rasika Waghmare¹, Tushar Patil²

¹Department of Radiology, Yashwantrao Chavan Memorial Hospital, Pimpri-Chinchwad, Maharashtra, India, ²Department of Pathology, Yashwantrao Chavan Memorial Hospital, Pimpri-Chinchwad, Maharashtra, India

Abstract

Tuberculosis being endemic in country like India can affect any organ though pulmonary tuberculosis is rampant and extrapulmonary is rare. Tuberculosis affecting parotid gland is a rare occurrence, usually unilateral. However, Mycobacterium tuberculosis causing cold abscess in bilateral parotid glands is even rarer. Here, we present a case of a young female presented with bilateral slow-growing swelling in the parotid region with evening raise of temperature for two months. On clinical examination, no signs of inflammation were seen. Ultrasonography showed thick-walled hypoechoic collection with septae and internal echoes within involving both superficial and deep lobes of the parotid gland. Fine-needle aspiration cytology (FNAC) suggested a caseating granuloma and acid fast bacilli were detected on ZN staining, thereby confirming the diagnosis of cold abscess. She was put on antitubercular drugs and there was a drastic reduction in the size of swelling.

Keywords: Bilateral, cold abscess, parotid, TB, tubercular

INTRODUCTION

Tuberculosis is a chronic granulomatous infection with varied clinical presentation and wide distribution. Although pulmonary tuberculosis is very rampant, extrapulmonary tuberculosis (EPTB) is an emerging problem as it has a diagnostic dilemma and management controversy. In India, the incidence of EPTB ranges from 20% to 30%.^[1-4] The involvement of the parotid gland is quite rare and bilateral involvement is even more infrequent, even in an endemic country like India, and merely hundred cases have been reported in literature.^[5,6] It is most commonly misdiagnosed as parotid neoplasm due to lower incidence and non specific signs and symptoms.^[7]

Here, we discuss a case of bilateral parotid tubercular cold abscess in a 14-year-old girl, whose clinical presentation and radiological findings laid a diagnostic dilemma. Fine-needle aspiration cytology helped diagnose cold abscess and the patient responded well to antitubercular drugs.

CASE REPORT

A young 14-year-old female presented with bilateral swelling in the parotid region for 2 months [Figure 1]. It was slow

growing, not associated pain or fever. There was no pus discharge or bleeding.

On local examination, there was bilateral swelling in the parotid region of approximate size of 10 cm × 5 cm × 3 cm. Both swellings were located approximately 2 cm in front of the ear lobule extending below the angle of the mandible and 4 cm away from symphysis menti, not reaching midline. Overlying skin showed no redness, scar, or sinus tract. Lesions were nonpulsatile.

On palpation, both swellings were nontender; there was no local rise of temperature. It was firm in consistency with positive fluctuation test. No palpable cervical lymph nodes. General systemic examination showed no significant abnormality.

Her laboratory report showed normal hemogram, liver function test, renal function test, and urine routine except for raised erythrocyte sedimentation rate value of 72mm/h.

Serological test for HIV and HBsAg was non reactive. Chest radiography [Figure 2] and ultrasonography (USG) of abdomen was normal.

Address for correspondence: Dr. Pooja Jaisinghani, Department of Radiology, Yashwantrao Chavan Memorial Hospital, Pimpri-Chinchwad, Maharashtra, India. E-mail: jaisinghani33pooja@gmail.com

Received: 21-10-2022 Revised: 20-12-2022 Accepted: 06-01-2023 Available Online: 13-04-2023

Access this article online

Quick Response Code:



Website:
<https://journals.lww.com/jmut>

DOI:
10.4103/jmu.jmu_108_22

This is an open access journal, and articles are distributed under the terms of the Creative Commons Attribution-NonCommercial-ShareAlike 4.0 License, which allows others to remix, tweak, and build upon the work non-commercially, as long as appropriate credit is given and the new creations are licensed under the identical terms.

For reprints contact: WKHLRPMedknow_reprints@wolterskluwer.com

How to cite this article: Udagi C, Jaisinghani P, Waghmare R, Patil T. Cold abscess of bilateral parotids: Delusion or reality? J Med Ultrasound 2024;32:175-8.

USG of local swellings in the bilateral parotid region showed a thick-walled hypoechoic collection replacing majority of bilateral parotid glands giving a claw sign with rest of the parotid glands being normal [Figure 3]. Collection was seen involving both superficial and deep lobes of the bilateral parotid glands [Figure 4].

The collection showed thick septate and coarse internal echoes within. No significant internal vascularity was seen; minimal peripheral and septal vascularity was seen. No solid mass lesion or calcification was seen within lesion.

Multiple subcentimeter-sized rounded hypoechoic necrotic lymph nodes were seen surrounding collection and within bilateral parotid glands [Figure 5].

No significantly enlarged cervical lymph nodes were found.

On USG guided FNAC, a yellowish caseous thick purulent fluid was aspirated from both sides. On microscopic evaluation, it showed areas of proteinaceous material admixed with loose epithelioid cell collections and occasional Langhans giant cells [Figure 6]. On Ziehl-Neelsen (ZN) stain, morphologically typical as well as atypical acid fast mycobacteria were seen. Fine-needle aspiration cytology (FNAC) was diagnostic of caseating granulomatous inflammation in bilateral parotid region suggestive of tubercular cold abscess.

The patient was started on “intensive phase” of antitubercular drug regimen consisting of isoniazid + rifampicin + pyrazinamide + ethambutol for 8 weeks and showed

good response with significant reduction in size (approximately 30%) of swelling on 1-week follow-up USG [Figure 7]. This was followed by 16 weeks of “continuation Phase” regimen which is excluding pyrazinamide from the “intensive phase”.

DISCUSSION

Tuberculosis is a chronic granulomatous inflammation caused by *Mycobacterium tuberculosis* with varied clinical presentations, which therefore needs high clinical suspicion. Its incidence is high in developing countries, like India.^[8] However, nowadays, it is increasing in developed countries too due to the emergence of resistance strains and coinfection with HIV.^[3,8,9]

Despite tuberculosis commonly involving the lungs, extrapulmonary forms are not at all uncommon and account for approximately 20% of overall active tuberculosis, but the salivary glands appear to be rarely infected.^[1,3] This may be due to the inhibitory effect of saliva on mycobacteria due to the presence of thiocyanate ions and proteolytic enzymes, such as lysozyme. In addition, the continuous flow of saliva prevents the inoculation of mycobacteria within the gland



Figure 1: Clinical picture of our case showing swelling in the bilateral parotid region

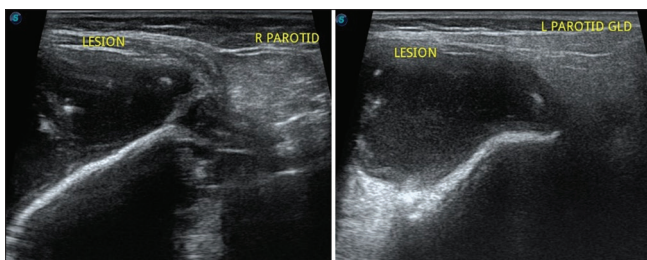


Figure 3: Lesions in both parotid glands with normal remnant gland seen on the left side of both images

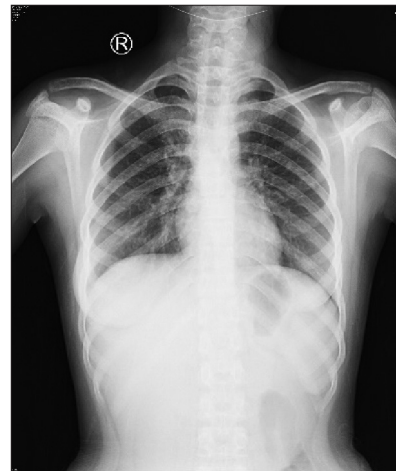

Figure 2: PA view of chest X-ray showing no significant abnormality

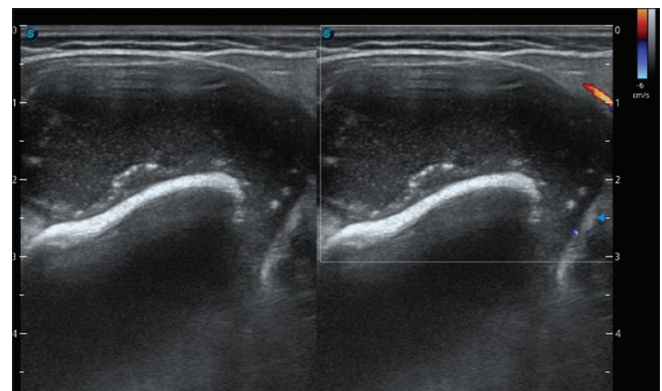


Figure 4: Hypoechoic fluid-filled lesion with internal echoes and no significant vascularity involving both superficial and deep lobes of the bilateral parotid gland

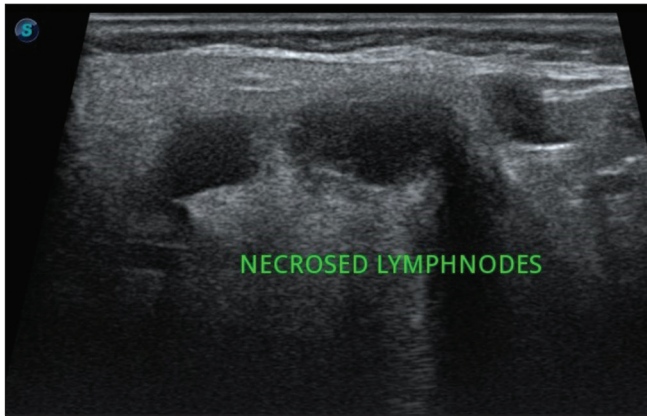


Figure 5: Periglandular necrotic lymph nodes

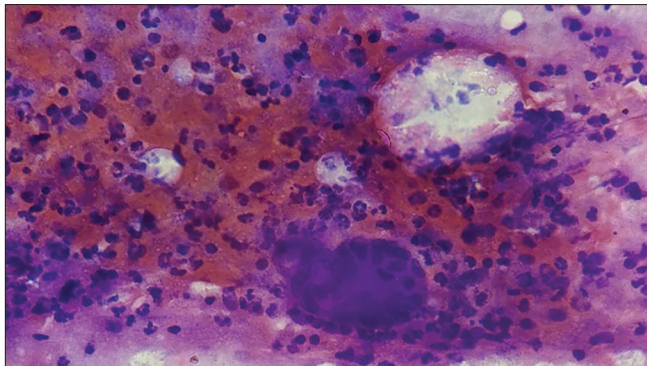


Figure 6: FNAC showing areas of proteinaceous material admixed with loose epithelioid cell collections and a Langhans giant cell. FNAC: Fine-needle aspiration cytology

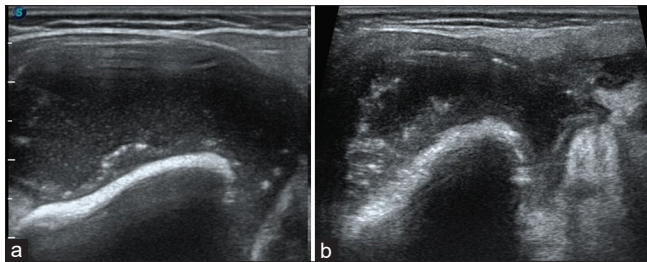


Figure 7: (a) Lesion before treatment; (b) reduction in size after antitubercular drug

parenchyma.^[5,8] Bilateral involvement of the parotid gland is even more uncommon.^[6] The first case of tubercular parotitis was diagnosed in 1893 by C De Poali.^[5,6] Since then, only about few hundred cases have been reported in the literature, mostly following the parotidectomy.^[8,10]

Mycobacteria gain access to parotid gland by two different modes, first by the oral infection (teeth and tonsillar tissue) or by autoinoculation with infected sputum, which reaches the parenchyma and/or lymphatics of the parotid gland by the afferent lymphatics or by ducts. Hematogenous or lymphatic spread from another distant primary lung focus is the second pathway.^[5] In our case, since chest X-ray was normal, the first mode of spread is highly possible, i.e., primary pathway.

Tuberculous involvement of the parotid gland can occur in various forms. One of it is diffuse parenchymal disease resembling acute sialadenitis which on USG appears as a diffusely enlarged hypoechoic gland with or without focal intraparotid anechoic zones.^[6] Another is involvement of intraglandular lymph nodes presenting as localised slowly growing mass simulating a neoplasm. It appears as hypoechoic nodules seen in the peripheral zone on the background of hyperechoic parotid gland on USG.^[6] The intraglandular lymph nodes' involvement is more common.^[3,11] The salivary gland register (1965–1981) contains only 2 cases of parenchymatous tuberculosis of the parotid gland. However, it contains 46 cases of intraglandular or periglandular lymph node involvement.^[12] The ratio of parenchymatous to periglandular lymph node involvement is 1:23. Both forms may occur separately or in combination. It may also present as a preauricular fistula or as abscess.^[8] In our case, both parenchyma and lymph nodal involvement seen with cold abscess formation in bilateral parotid gland, suggesting the late stage of the disease process.

Absence of any clinical symptoms and signs of tuberculosis or clinical lung disease would lead to misdiagnosis of parotid tuberculosis. Especially when bilateral involvement is there, high clinical suspicion is needed. Imaging and FNAC are helpful in the diagnosis of parotid tuberculosis.^[8] In our case since, other primary source of tuberculosis was not found and in the absence of symptoms and signs of tuberculosis, bilateral intraparotid hypoechoic fluid filled lesions on USG would have mislead more toward cystic neoplasm involving both parotid glands.

FNAC is a reliable and useful diagnostic tool for parotid tuberculosis.^[8] In parotid lesions, FNAC has a sensitivity of 81%–100% and specificity of 94%–100%.^[8,13] In our case, caseating pus was aspirated and on cytology, cluster of epithelioid cells with occasional Langerhans giant cells were seen - consistent with tuberculosis. ZN stain further confirmed the acid fast bacilli.

Hence, early diagnosis and conservative management with antitubercular drugs were possible, for which our patient responded drastically.

CONCLUSION

Tuberculosis has been a major cause of suffering and death since times immemorial and most of extrapulmonary cases present with nonspecific signs and symptoms. Parotid tuberculosis presenting bilaterally is extremely rare. Hence, high clinical and diagnostic imaging suspicion is required even when disease is bilaterally affected. This would differentiate surgically treatable disease from medically treatable disease and lessen patient's economic burden and stress.

Declaration of patient consent

The authors certify that they have obtained all appropriate patient's guardian consent form. In the form the guardian has given the consent for the child's images and other clinical

information to be reported in the journal. The guardian understands that the child's name and initials will not be published and due efforts will be made to conceal identity, but anonymity cannot be guaranteed.

Financial support and sponsorship

Nil.

Conflicts of interest

There are no conflicts of interest.

REFERENCES

1. Lee IK, Liu JW. Tuberculous parotitis: Case report and literature review. *Ann Otol Rhinol Laryngol* 2005;114:547-51.
2. Hamdan AL, Hadi U, Shabb N. Tuberculous parotitis: A forgotten entity. *Otolaryngol Head Neck Surg* 2002;126:581-2.
3. Birkent H, Karahatay S, Akcam T, Durmaz A, Ongoru O. Primary parotid tuberculosis mimicking parotid neoplasm: A case report. *J Med Case Rep* 2008;2:62.
4. Gupta V, Patankar K, Shinde A, Bhosale C, Tamhane A. Tuberculosis of the parotid gland. *Case Rep Radiol* 2012;2012:278793.
5. Janmeja AK, Das SK, Kochhar S, Handa U. Tuberculosis of the parotid gland. *Indian J Chest Dis Allied Sci* 2003;45:67-9.
6. Takhar R, Bunkar M, Jangid V, Saxena A. Bilateral parotid gland tuberculosis: A rare occurrence. *Egypt J Chest Dis Tuberc* 2015;64:653-6.
7. Paruthy S, Paruthy SB. Parotid gland tuberculosis-presentation of 4 case variants. *Int Surg J* 2021;8:984-7.
8. Jain A, Meher R, Wadhwa V, Raj A, Tandon S. Parotid tuberculosis: A diagnostic dilemma. *Acta Otolaryngol Case Rep* 2017;2:73-6.
9. Erkan AN, Cakmak O, Kayaselçuk F, Köksal F, Ozlüoğlu L. Bilateral parotid gland tuberculosis. *Eur Arch Otorhinolaryngol* 2006;263:487-9.
10. Dixit R, Shah V, Dixit K, Solanki RN, Kotadia J. Tuberculous abscess of parotid gland. *J Ind Acad Clin Med* 2005;6:161-3.
11. Zhang D, Li X, Xiong H, Yang C, Lv F, Huang X, *et al.* Tuberculosis of the parotid lymph nodes: Clinical and imaging features. *Infect Drug Resist* 2018;11:1795-805.
12. Holmes S, Gleeson MJ, Cawson RA. Mycobacterial disease of the parotid gland. *Oral Surg Oral Med Oral Pathol Oral Radiol Endod* 2000;90:292-8.
13. Iseri M, Aydinler O, Celik L, Peker O. Tuberculosis of the parotid gland. *J Laryngol Otol* 2005;119:311-3.