

# A Male Patient with Severe Pain in the Right Hypochondrium

Rohit Ravindra Joat\*, Suresh Vasant Phatak, Azhar Shoaib Shaikh, Gajanan K. Wattamwar, Ganesh S. Narwane  
 Department of Radiodiagnosis and Imaging, NKP Salve Institute and Research Centre, Nagpur, Maharashtra, India

## SECTION 1 – QUIZ

### Case

A 45-year-old male presented with complaints of pain in the right hypochondrium for 6 months, which was aggravated in

the last 10 days. There was no history of trauma. Ultrasound and computed tomography evaluation of the abdomen were performed [Figures 1-3].

### Declaration of patient consent

The authors certify that they have obtained all appropriate patient consent form. In the form, the patient has given his consent for his images and other clinical information to be reported in the journal. The patient understands that his name and initials will not be published, and due efforts will be made to conceal the identity, but anonymity cannot be guaranteed.

### Financial support and sponsorship

Nil.

### Conflicts of interest

There are no conflicts of interest.

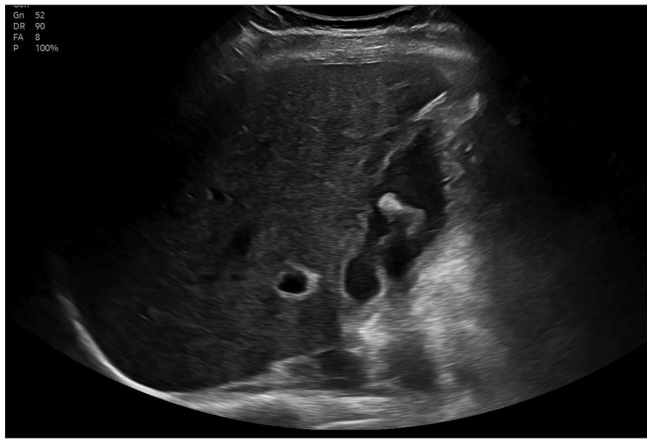

Figure 1: Grayscale ultrasound image of the liver and gallbladder

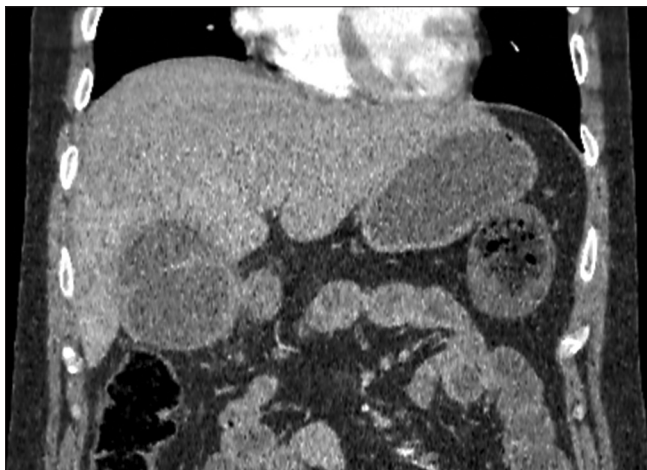


Figure 3: Computed tomography image of the abdomen

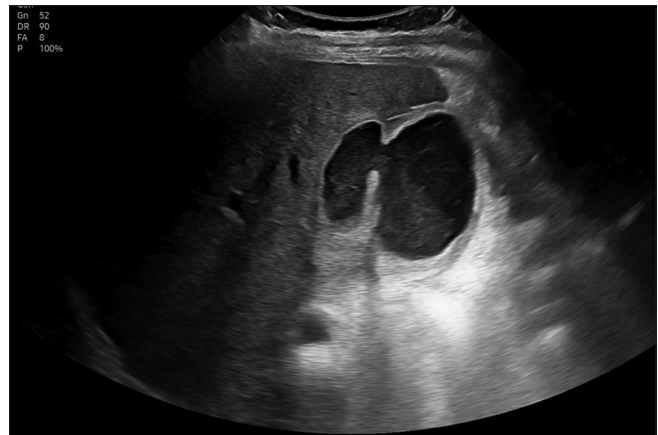

Figure 2: Grayscale ultrasound image of the gallbladder

**Address for correspondence:** Dr. Rohit Ravindra Joat,  
 Department of Radiodiagnosis and Imaging, NKP Salve Institute and  
 Research Centre, Digidoh Hills, Nagpur - 440 019, Maharashtra, India.  
 E-mail: jrohit00001@gmail.com

Received: 24-07-2023 Accepted: 18-08-2023 Available Online: 27-10-2023

### Access this article online

#### Quick Response Code:



Website:  
<https://journals.lww.com/jmut>

DOI:  
 10.4103/jmu.jmu\_89\_23

This is an open access journal, and articles are distributed under the terms of the Creative Commons Attribution-NonCommercial-ShareAlike 4.0 License, which allows others to remix, tweak, and build upon the work non-commercially, as long as appropriate credit is given and the new creations are licensed under the identical terms.

For reprints contact: WKHLRPMedknow\_reprints@wolterskluwer.com

**How to cite this article:** Joat RR, Phatak SV, Shaikh AS, Wattamwar GK, Narwane GS. A male patient with severe pain in the right hypochondrium. J Med Ultrasound 2024;32:367.